

# Head Positioning Error in Cephalometric Radiography

## — an Implant Study

John L. Spolyar

An experimental quantification of changes in position of cephalometric images caused by variation in head rotation in successive radiographs.

KEY WORDS: • CEPHALOMETRICS • IMPLANTS • RADIOGRAPHY •

Cephalometric radiography is an anthropometric technique which standardizes magnification and related distortions of the x-ray image (BROADBENT 1931). Magnification has been reviewed by many authors, including THUROW (1951, 1977) and BERGERSEN (1980). It is generally recognized that most changes in the position of the head in the cephalostat will produce changes in image size and position; however, serial changes caused by inconsistent head positioning in standardized cephalometry have not been subjected to objective analysis.

Differences in head rotation will cause differences in image position for bilateral structures such as the mandibular rami and corpi, greater sphenoid wings, roofs of the orbits, key ridges, anterior orbital outlines, pterygopalatine fossae, and dentition. Differences in distance from the x-ray film will cause differences in image size. The combined effects of these two types of image distortion are often difficult to control or assess.

The problem of measurement of dual images of bilateral structures has been largely overcome in tracing lateral cephalographs by drawing a line between the images of homologous bilateral structures, which in effect averages the position of the bilateral anatomy to the midsagittal plane. If a change in the pattern of the dual image of bilateral structures should occur between successive x-rays, this same averaging technique will practically compensate for the difference. However, this approach cannot differentiate between geometric distortions and actual subject asymmetry, so it also obliterates asymmetry by averaging asymmetric structures.

---

*Author Address:*

Dr. John L. Spolyar  
35129 Dodge Park  
Sterling Heights, MI 48077

Dr. Spolyar is Staff Orthodontist at the Cleft Lip/Palate and Craniofacial Anomaly Clinic and Director of Orthodontic Services at the Children's Hospital of Michigan in Detroit, Michigan; Assistant Clinic Professor, Department of Orthodontics, University of Detroit; and in the private practice of orthodontics in Sterling Heights, Michigan. He is a dental graduate (D.D.S.) of the University of Michigan, and holds an M.S. degree in orthodontics from the University of Detroit.

## Spolyar

Effects on image size can be quite subtle, either increasing or decreasing the size of the image of sagittal structures, or the average size of bilateral structures, in proportion to the amount of head positioning error.

To illustrate this point, one can assume a cephalometric setup for a lateral view with a focal-film distance of 165cm, and an object-film distance of 15cm from the sagittal plane to the film surface. For a sagittal anatomic component in a lateral cephalograph, the effect of a 5° rotation in alignment with that component would reduce the image length by 0.4% ( $1 - \cos 5^\circ \times 100 = 0.4\%$ ). The expected 100mm image of a Ba-N cranial base dimension would be artifactually reduced to 99.6mm by such a 5° rotation out of the plane perpendicular to the x-ray beam.

Using the same geometry, a pair of bilateral structures such as a bigonial width of 115mm might show an image parallax separation of 11mm in a lateral cephalograph at 10% magnification. A split-image tracing would compensate for the image separation; however, the 5° rotation would shift the tracing showing average corpus length (Go-Pog) out of the sagittal plane, with nearly 0.4% foreshortening of corpus length.

Where there is a need for a unilateral analysis, as in hemifacial microsomia, these factors can become important. The amount and direction of image shift resulting from a change in head position within the cephalostat from one film to the next is generally unknown and unquantifiable. Even beyond the special problems of unilateral analysis, it is generally important to know the amount of head positioning error that can be expected between serial cephalographs and the effect, if any, on quantification of specific changes.

The purpose of this study is to:

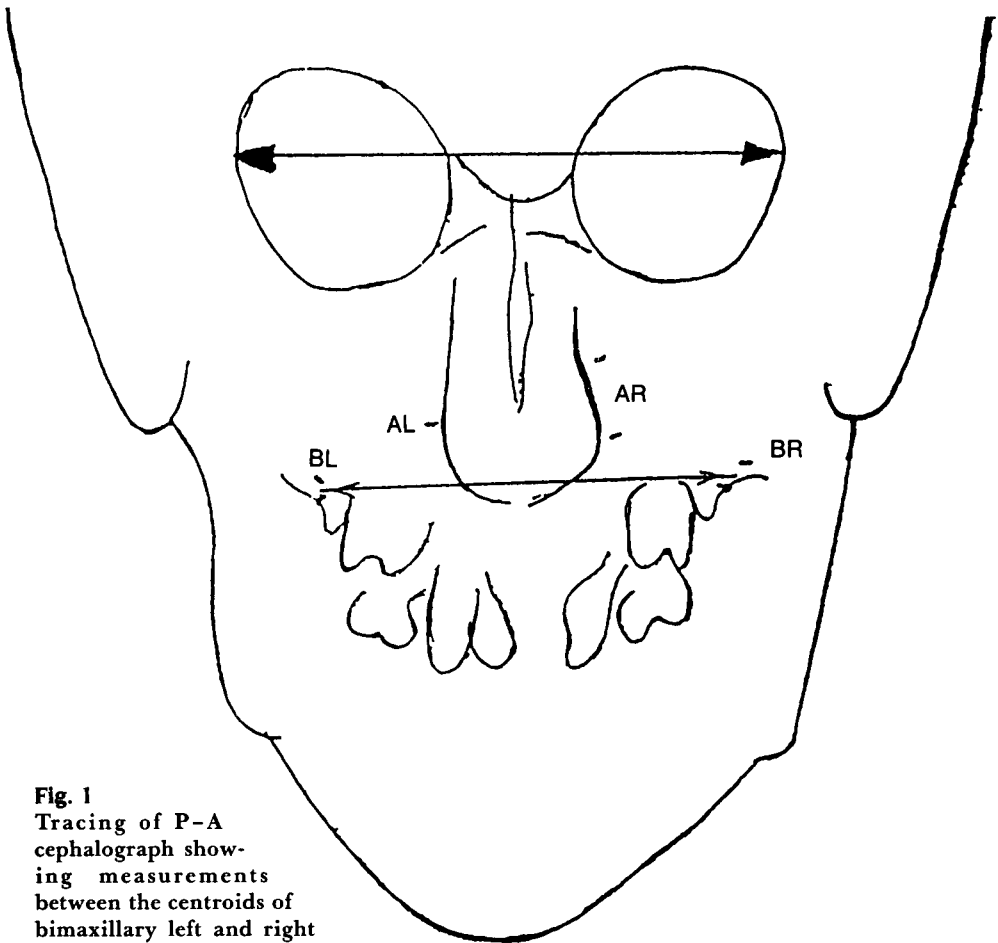
- Present a method for quantifying the amount and direction of shift in head position between successive standardized cephalographs.
- Define the amount and direction of head positioning error within a study group.
- Correlate the above findings with shifting of recognized anatomic landmarks.

### — Methods and Materials —

Tantalum bone markers were placed in various craniofacial regions in twenty subjects for reasons unrelated to this study. All radiographs were taken with a 165cm focal-film distance and 15cm film distance from the sagittal plane. The cephalographs were exposed under clinical conditions in which more than one trained technician performed the actual patient positioning and exposure. The same cephalostat was used for all exposures.

Two serial lateral cephalographs and one P-A cephalograph were used for each evaluation. Two or three bone markers were present on each side of the anatomic references in nearly all subjects, so that implant stability could be checked. When a solitary marker was present unilaterally, cross-checking against other markers in other bony components within the subject was done to verify implant stability.

Bone marker movement is most common immediately after implantation (RUNE ET AL. 1979). Therefore, the initial post-implantation radiographs were not used in this study. Because palate expansion, orthognathic surgery, and other orthopedic procedures can also relocate the anatomic structures and possibly realign the markers, no treatment procedures were done in the interval between exposure of lateral cephalographs used in this study.



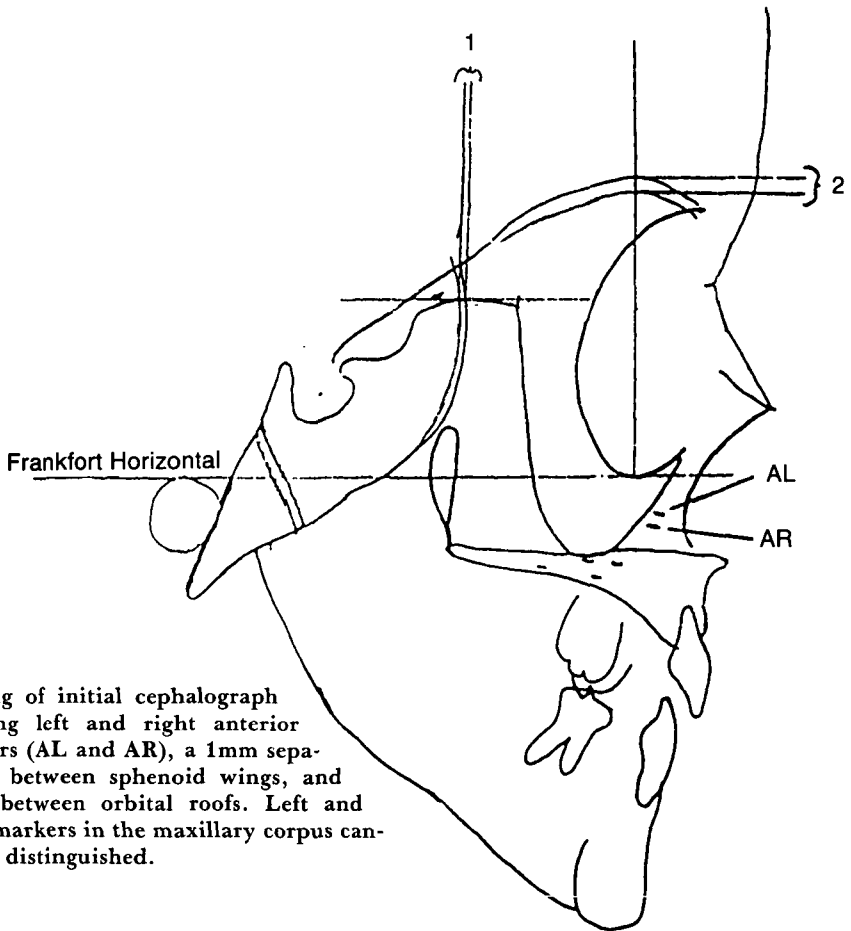
**Fig. 1**  
Tracing of P-A cephalograph showing measurements between the centroids of bimaxillary left and right (BL and BR) markers, and between outer orbital margins. Anterior markers (AL and AR) are also shown.

### ***Determination of head shift***

1. For each P-A cephalograph the left and right bone markers were traced on .003" acetate film and their separation measured (Fig. 1). Unilateral points were established at the centroid of 2 or 3 markers, or a single marker was used. Measurements were made to the nearest

millimeter and corrected for 10% magnification.

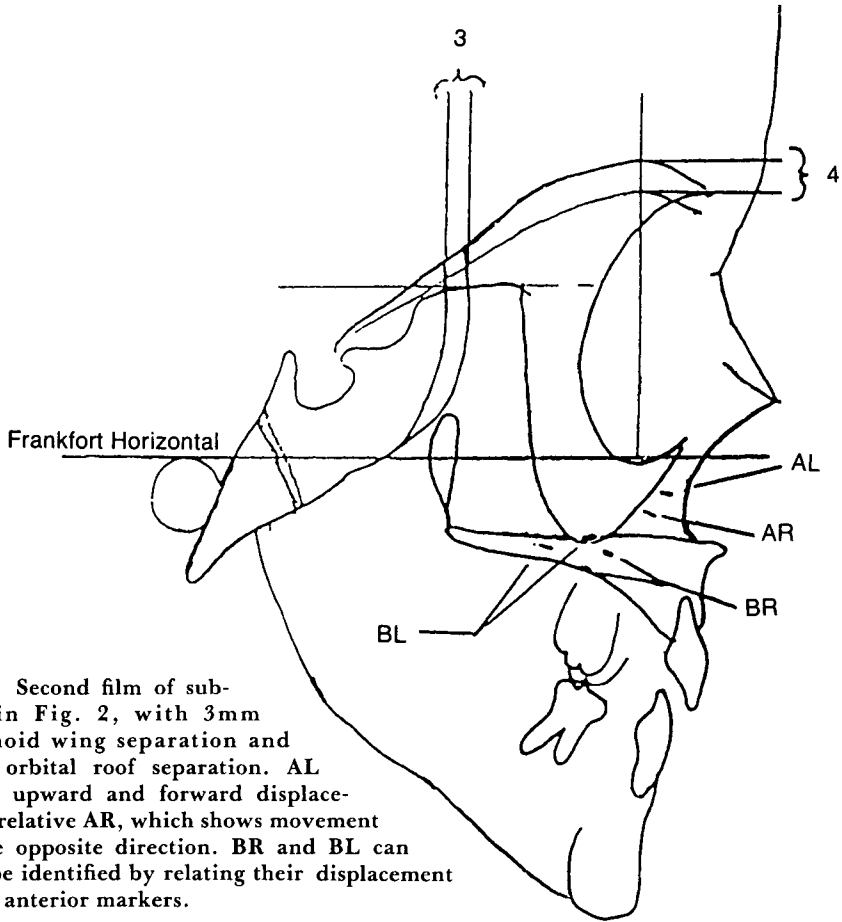
2. For each lateral cephalograph the pattern of the above markers was recorded on another acetate tracing, and a hole made in the center of each bone marker image with a sharp sewing needle (Figs. 2 and 3). On one tracing a line representing the Frankfort Horizontal was also drawn (Fig. 4).



**Fig. 2**  
Tracing of initial cephalograph showing left and right anterior markers (AL and AR), a 1mm separation between sphenoid wings, and 2mm between orbital roofs. Left and right markers in the maxillary corpus cannot be distinguished.

3. Comparisons were made with the lateral tracings overlaid, with two or more markers with the greatest separation on the same side (Fig. 5).
4. The "free" markers, on the side contralateral to the reference markers, were recorded on the tracing with the Frankfort horizontal, and the distance between free and reference markers recorded to the nearest 0.2mm.
5. A line connecting each pair of free markers was extended to pass through the FH plane, and the angle formed with the FH plane recorded to the nearest degree ( $\alpha$ , Fig. 5).

6. The distance between the images of a free marker pair, representing the shift between exposures, was divided by their left-right separation to give the shift of the head in radians,  $r$ .
7. The radial shift was divided into horizontal and vertical components. The vertical component of radial image shift is equal to  $r \times \sin \alpha$ . The horizontal component of radial image shift is equal to  $r \times \cos \alpha$  (Fig. 6). Radians were converted to degrees for presentation of the results ( $\text{radians} \times 180/\pi = \text{degrees}$ ).



**Fig. 3** Second film of subject in Fig. 2, with 3mm sphenoid wing separation and 4mm orbital roof separation. AL shows upward and forward displacement relative AR, which shows movement in the opposite direction. BR and BL can now be identified by relating their displacement to the anterior markers.

8. The horizontal separation between the greater sphenoid wings at the sphenoid plane parallel to the FH plane was recorded to the nearest 0.5mm for each lateral cephalograph (Figs. 2 and 3).

9. The vertical separation between the orbital roof outlines at their highest point of contour on a line perpendicular to FH was recorded for each lateral cephalograph to the nearest 0.5mm (Figs. 2 and 3).

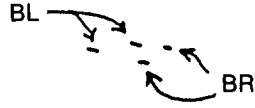
10. In 8 and 9 above, the differences between measurements represent the

amount of relative horizontal or vertical shift of the images of the anatomic landmarks.

A skull mannequin with bone markers in the occipital, temporal, and zygomatic bones was used to check the above method (Figs. 7 and 8). A postero-anterior and three lateral cephalographs were taken at  $0^\circ$ ,  $2.39^\circ$  and  $5.37^\circ$  of rotation in the horizontal plane. This was done by measured rotation of the cephalostat on its 3" radius hub. Radiographs of the mannequin were treated in the same manner as those of the study subjects.

Frankfort Horizontal

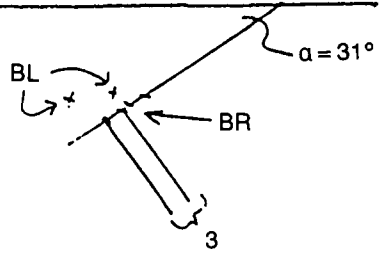
---



**Fig. 4** Tracing of the bimaxillary left and right (BL and BR) bone markers. Bone marker size is shown for graphic representation; pin holes were used to mark the center of bone marker positions in this study.

Frankfort Horizontal

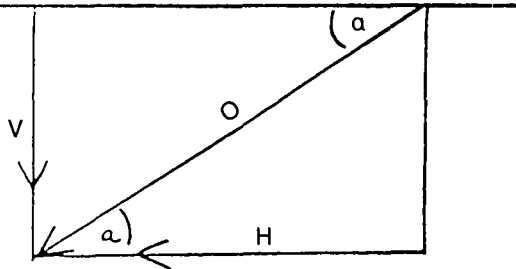
---



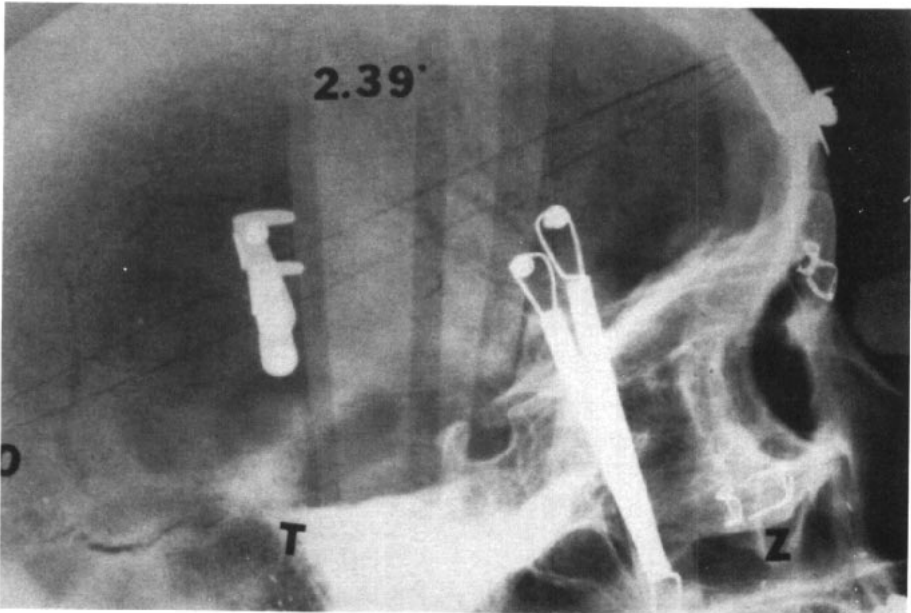
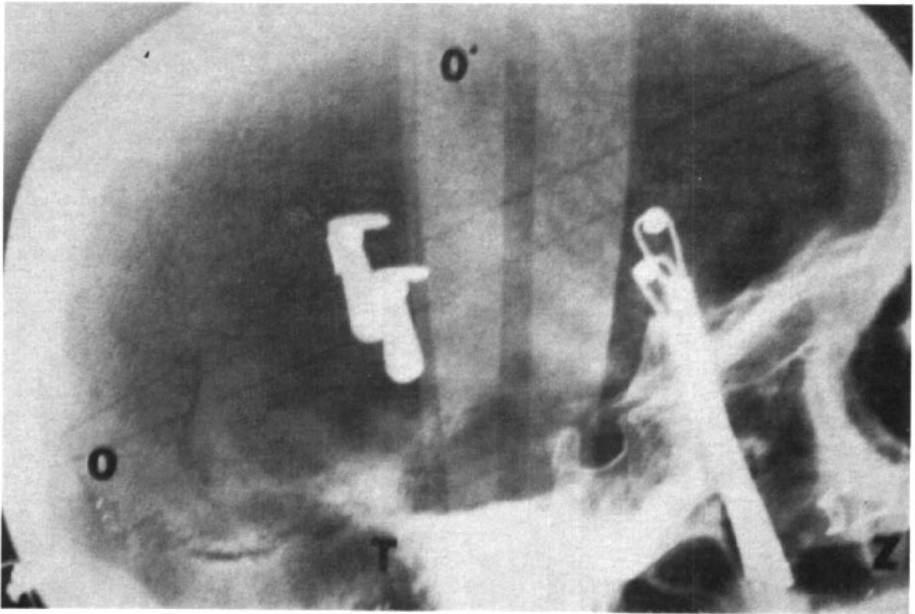
**Fig. 5** First and second implant registrations superimposed on the BL markers. The BR markers register the amount and direction of relative image displacement. A line through the centroids of the first and second BR images is referenced to FH by angle  $\alpha$ . The distance between first and second images shows a 3mm shift between successive lateral cephalographs.

Frankfort Horizontal

---

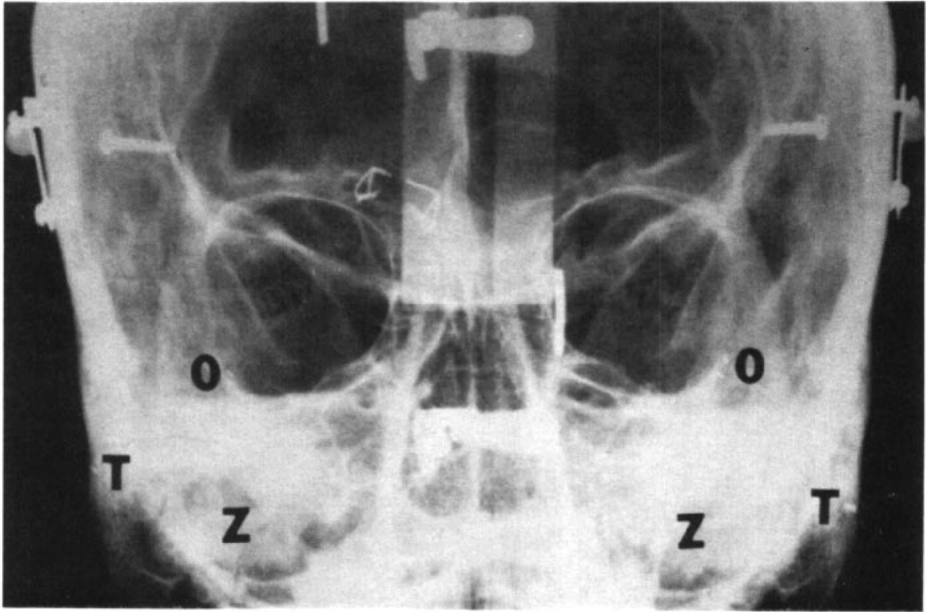


**Fig. 6** Derivation of vertical (V) and horizontal (H) components comprising the observed vector of movement (O) relative to Frankfort horizontal plane (angle  $\alpha$ ).  $V = \text{Sin}\alpha$  (O);  $H = \text{Cos}\alpha$  (O).



**Fig. 7** *top* Lateral cephalograph of a skull mannequin in a standard position in the cephalostat (zero degrees), showing the positions of the temporal markers.

*bottom* The mannequin in a 2.39° rotated position.



**Fig. 8** Postero-anterior cephalograph of the same skull, showing bilateral positions of the occipital (O), temporal (T), and zygomatic (Z) markers.

### — Results —

Results of the mannequin study are shown in Table 1. The calculated results closely match the experimental measurements, within 0.2mm or 0.17° in the worst case (Column 8).

The results from the study population are shown in Tables 2 and 3. Average lateral spacing of the implanted landmarks is 67mm. Head positioning error in the lateral views shows a mean image shift of 1.7mm between bilateral implants, with a range of 0.5mm to 6.2mm. The average angular change was 1.59°, with a range from 0° to 5.23°. Three of the twenty study subjects had no measurable head positioning difference between successive lateral cephalo-

graphs, and four had more than 2° difference in head rotation.

There was no predominance of direction of image shift. Nine of the seventeen subjects with a measurable shift showed a direction of image shift within 44° of the Frankfort horizontal; the other eight were 45° or more.

The overall average vertical component of image shift was 0.80°, and for the seventeen subjects with a detectable shift it was 1.1°. The horizontal component averaged 1.06° for all subjects, and 1.25° for those with a measurable difference. Eight of the twenty showed a horizontal image shift in excess of 1°.

The shift of the sphenoid wings (Table 3) ranged from 0 to 5.5mm, with a 1.38mm mean. When one degree or more



Table 1

Mannequin Implant Image Displacement With Measured Rotation of the Sagittal Plane A — Sagittal Plane Parallel with the Film B — 2.39° horizontal rotation C — 5.37° rotation							
	Implant Location	Bilateral Separation	Actual Shift	Calculated Shift	Actual Rotation	Calculated Rotation	Difference
A to B	Occipital	78.4	3.27	3.1	2.39°	2.26°	-.13°
A to C	Occipital	78.4	7.35	7.5	5.37°	5.48°	+.11°
A to B	Temporal	125.	5.25	5.1	2.39°	2.34°	-.05°
A to C	Temporal	125.	11.73	11.9	5.37°	5.46°	+.09°
A to B	Zygomatic	70.3	2.93	2.9	2.39°	2.36°	-.03°
A to C	Zygomatic	70.3	6.6	6.8	5.37°	5.54°	+.17°

Table 2

Displacement of Implant Images in Successive Exposures Linear distances in millimeters							
Subject and Implant location	Bilateral Implant Separation	Image Shift	Shift angle to FH	Head Rotation	Vertical Head Rotation	Horizontal Head Rotation	
1 MX	63	0	0°	0°	0°	0°	
2 MX	71	0	0°	0°	0°	0°	
3 MX	68	0	0°	0°	0°	0°	
4 MX	75	0.5	0°	0.38°	0°	0.38°	
5 MX	57	2.5	3.0°	2.50°	0.13°	2.49°	
6 MD	68	6.2	6.0°	5.23°	0.55°	5.2°	
7 MX	67	1.4	11.0°	1.20°	0.23°	1.18°	
8 MX	58	1.6	13.0°	1.58°	0.36°	1.54°	
9 MD	51	1.0	25.0°	1.18°	0.49°	1.06°	
10 MD	69	0.8	25.0°	0.70°	0.29°	0.63°	
11 MX	63	1.8	34.0°	1.64°	0.92°	1.36°	
12 MX	63	1.8	44.0°	1.64°	1.14°	1.18°	
13 MD	67	3.5	45.0°	3.00°	2.12°	2.12°	
14 MX	68	1.4	46.0°	1.18°	.85°	.82°	
15 MD	75	1.6	50.0°	1.22°	.93°	.78°	
16 MD	78	1.5	55.0°	1.10°	.90°	.63°	
17 MX	45	1.5	62.0°	1.91°	1.69°	.90°	
18 MX	65	2.0	73.0°	1.76°	1.67°	.52°	
19 T	100	2.0	82.0°	1.15°	1.14°	.15°	
20 MX	64	3.0	85.0°	2.69°	2.68°	.23°	
Overall Average	67	1.7		1.59°	0.80°	1.06°	
Average of measurable shifts		2.0		1.87°	1.10°	1.25°	

Table 3

Displacement of Anatomic Images in Successive Exposures  
Changes in Image Separation in millimeters

Subject	Outer Orbital Width	Sphenoid Wing			Roof of Orbit		
		First	Second	Shift	First	Second	Shift
1	102	4.0	4.0	0	3.5	4.0	.5
2	103	2.0	2.0	0	4.5	4.5	0
3	103	4.5	4.5	0	4.0	4.0	0
4	95	2.5	2.0	0.5	5.5	5.5	0
5	92	5.0	7.0	2.0	3.0	3.5	0.5
6	91	2.0	7.5	5.5	3.0	3.5	0.5
7	100	5.5	6.5	1.0	4.9	4.9	0
8	99	2.5	4.0	1.5	2.5	2.5	0
9	97	3.0	3.6	0.6	3.5	4.5	1.0
10	93	5.0	5.0	0	0	0	0
11	98	2.5	3.5	1.0	0	0	0
12	100	1.5	2.0	0.5	3.5	*	*
13	96	5.0	7.0	2.0	3.0	6.0	3.0
14	95	2.0	3.0	1.0	3.5	4.5	1.0
15	102	9.0	9.0	0	3.5	3.5	0
16	95	3.0	3.5	.5	7.0	7.5	.5
17	93	7.0	7.5	.5	0	2.0	2.0
18	94	2.5	2.5	0	3.0	4.5	1.5
19	*	*	*	*	*	*	*
20	90	10.5	10.5	0	2.0	-2.0	4.0
Overall Average	97			1.06			.81
Average of measurable shifts				1.38			1.45

of image shift occurred, consistently detectable shifts of the anatomic landmarks were seen in both cardinal planes of space, such as vertical shift of the orbital roofs and horizontal shift of the sphenoid wings.

A computation of the left-to-right sphenoid wing dimension gives a mean of 57mm, which is about 59% of the average outer orbital dimension as measured on the P-A cephalograph and adjusted for the 10% magnification. The

average left-right orbital roof separation was 76mm or 78% of the outer orbital dimension. This means that the shifts in many important landmarks will be greater than those reported for the test points.

— Discussion —

The measurement technique used to determine head position error is very accurate, calculated at no greater than

.17° (.003 radians) from the measured image shift. This represents an error of .3mm in the worst case, with the points separated by 10cm in the plane parallel to the x-ray beam.

The measured errors for the phantom were more in accordance with themselves than with the calculated error, since they were all either less than 2.39° or greater than 5.37°. Perhaps the measured results are a better representation of reality than what was calculated from direct measurement on the hub of the cephalostat.

This study demonstrates significant head positioning error in 85% of the serial cephalometric surveys, with an average error of 1.59° (0.0277 radians).

The change in separation of the images of bilateral structures in successive standardized cephalographs is a function of the distance between the bilateral structures and differences in the rotation of the head. The relative shift of left and right images can occur in any direction in the two dimensions of the film — horizontal, vertical, or some combination of the two. This principle can be illustrated using the 1.59° average average variation in head position. The gonial angle images on a cephalograph represent one of the widest bilaterally homologous anatomic components of interest to orthodontists. With a bigonial dimension of 114.6 mm, the change in relative position of the gonial angle images with the 1.59° average variation would be 3.52 mm.

With the amount of error found in this study, positioning error must be considered in unilateral analysis of change in successive standardized radiographs. The average positioning error of 1.87°, occurring 85 percent of the time, would result in a parallax error of 3.73 mm in the above example.

The tracing technique of splitting the image of bilateral components compensates for most of the error introduced by

such image shifts, making it a practical approach where it is applicable. However, BERGERSEN (1980) has demonstrated that averaging the images does not yield an average component with the same magnification as a component in the midsagittal plane. A shift in head position may add to this minor disproportion in magnification, emphasizing the need for controlling head position error.

The inability to consistently detect head positioning errors less than 1° in the greater sphenoid wing or the orbital roof images may be because these landmarks represent a curved surface rather than a discrete anatomic point in space. Rotating the head can bring a different part of the structure into the position represented by the image on the film. BERGERSEN (1980) has suggested the possibility of this kind of error related to some anatomic landmarks.

Nevertheless, one can roughly estimate the positioning error in a vertical direction by determining the difference in the separation between the orbital roof images and dividing by 78% of the outer orbital dimension to yield the radians of shift. Multiplying radians by  $180/\pi$  will convert this value to the image shift in degrees. A similar computation can be made to estimate horizontal image shift error by dividing the sphenoid separation difference by 59% of the outer orbital dimension.

Any error above 5° may introduce significant artifactual error into linear measurements greater than 10cm.

This study, although showing variability in cephalostat head position, underscores the basic validity of cephalometric radiography for anthropometry. Accurate tracing techniques can compensate for most of the image variability seen in serial cephalographs, but cannot compensate for all linear errors.

\_\_\_\_\_ references on next page

REFERENCES

Bergersen, E. O. 1980. Enlargement and distortion in cephalometric radiography: Compensation tables for linear measurements. *Angle Orthod.* 50:230-244.

Broadbent, B. H. 1931. A new X-ray technique and its application to orthodontia. *Angle Orthod.* 1:45-66.

Rune, B., Jacobsson, S., Sarnas, K. V., Selvik, G. 1979. A roentgen stereophotogrammetric study of implant stability and movement of segments in the maxilla of infants with cleft lip and palate. *Cleft Palate J.* 16:267-278.

Thurow, R. C. 1979. *Atlas of Orthodontic Principles*, Ed. 2. St. Louis, C. V. Mosby.

*The Author thanks Sandra Florio for her assistance in the preparation of the manuscript and Stan Majewski, D.D.S. and Michael Linebaugh, D.D.S. for copy reading and constructive criticism.*

# The Angle Orthodontist

*Founded in 1930 by the co-workers of Edward H. Angle, in his memory*

Volume 57

January, 1987

Number 1

Published quarterly by the  
Angle Orthodontists Research and Education Foundation, Inc.

*Officers:*

Lee R. Logan, *President*  
 James J. Baldwin, *Vice President*  
 Blaine S. Clements, *Secretary*  
 John S. Kloehn, *Treasurer*

*Directors:*

Irving D. Buchin  
 Robert L. Felix  
 John G. Ryan  
 Robert M. Rubin

*Editorial Board:*

Raymond C. Thurow  
 James L. Jensen  
 Elbert W. King  
 Donald R. Poulton  
 Everett Shapiro

Alton W. Moore, *Secretary Emeritus*

Arthur B. Lewis, *Editor Emeritus*

**Editor**

Dr. Raymond C. Thurow  
 Suite 201-205  
 6402 Odana Road  
 Madison, WI 53719  
 (608) 845 - 6242

**Manuscripts and correspondence related to publication should be directed to the Editor**

**Business Manager**

Dr. John S. Kloehn  
 Suite 406  
 100 West Lawrence St.  
 Appleton, WI 54911  
 (414) 739 - 5822

**Correspondence related to subscriptions and back issues should be directed to the Business Manager**

**Annual Subscription Rates**

U.S.A. ZIP Codes — \$20.00  
 Other Countries — \$24.00US

**Back Issues**

\$6.00US each, plus shipping  
 Write for Quantity Prices